

The Armed Forces Institute of Pathology  
Department of Veterinary Pathology

Conference Coordinator  
Matthew Wegner, DVM



WEDNESDAY SLIDE CONFERENCE 2010-2011

Conference 12

1 December 2010

Conference Moderator:  
Jim Raymond, DVM, Diplomate ACVP

---

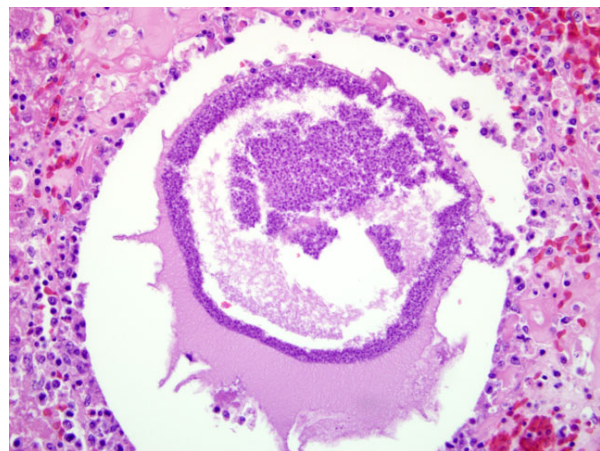
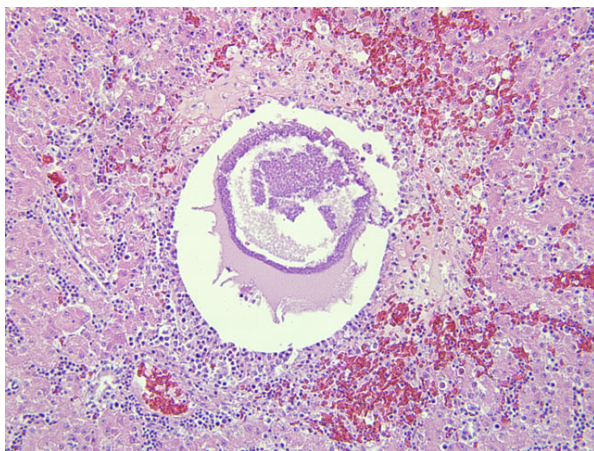
**CASE I:** M08-1488 (AFIP 3138058).

**Signalment:** 1-year-old, male, Quaker parrot (*Myiopsitta monachus*).

**History:** The bird died suddenly with no overt clinical signs. The local veterinarian performed a gross necropsy and reported that the liver was yellow with black flecks throughout. A single piece of formalin-fixed liver was submitted.

**Histopathologic Description:** Liver: The architecture of the liver is disrupted by large areas of hemorrhage

and coagulative necrosis, along with numerous degenerate cystic structures, interpreted to be ruptured protozoal megaloschizonts. Within both the necrotic areas and the cystic structures are scattered aggregates of approximately 3 $\mu$ m in diameter coccoid protozoal merozoites, some of which palisade along the remaining rim of the ruptured megaloschizonts. Scattered foci of lymphocytes and plasma cells are seen. Numerous clustered hepatocytes contain a moderate amount of brown, coarse granular, intracytoplasmic pigment.



I-1, I-2. Liver, parrot. Multifocally the architecture of the liver is disrupted by areas of hemorrhage and necrosis that surround cystic structures containing 3  $\mu$ m in diameter coccoid protozoal merozoites. (HE 200X)

**Contributor’s Morphologic Diagnosis:** Liver: Multifocal hepatocellular necrosis and hemorrhage, with ruptured protozoal megaloschizonts and mild lymphoplasmacytic hepatitis.

**Contributor’s Comment:** *Haemoproteus* spp. are hemoparasites which are typically of low pathogenicity in birds. However, infection can result in clinical disease in certain avian species, including pigeons, quail, and non-indigenous species, along with nestlings and immunocompromised hosts. Clinical signs of infection include hemolytic anemia, anorexia, and depression. Occasionally animals die suddenly with no overt clinical signs.<sup>4</sup>

The parasites are transmitted by blood-sucking insect vectors which ingest intraerythrocytic gametocytes when they feed. The gametocytes develop inside the insect host to become sporozoites within the salivary gland. These are injected into the new avian host when the insect feeds. The sporozoites enter the bird’s vascular endothelial cells, primarily those in the lung, liver, bone marrow, and spleen, where they undergo schizogony. Megaloschizonts are occasionally found in cytologic and histologic sections of infected tissue. These appear as large round cysts which contain numerous packeted zoites called cytomeres that rupture and release merozoites into the bloodstream. These enter erythrocytes and become gametocytes which are ingested by insect hosts to complete the life cycle.<sup>4</sup>

In two recent studies, none of the birds in which this disease is fatal demonstrated a detectable erythrocytic parasitemia.<sup>1,3</sup> This is likely due to peracute death associated with the pre-erythrocytic form of the parasite, which is speculated to cause host cell destruction with rupture of megaloschizonts, interference with circulation, and/or toxin release. The exact mechanism of death in these animals is still not completely understood.

**AFIP Diagnosis:** Liver: Hepatitis, random, neurohemorrhagic, acute to subacute, multifocally extensive, marked with protozoal megaloschizonts.

**Conference Comment:** Participants pursued discussion of a differential diagnosis list for megaloschizonts in birds; they generally agreed the list should include *Haemoproteidae*, *Leukocytozoidae*, and *Plasmodiidae*. Though all three groups of protozoa are related, there are distinct differences in the life cycles that, when present, serve as useful diagnostic aids. The chart below summarizes key life cycle, morphologic and diagnostic criteria.<sup>2,5</sup>

The moderator and participants commented on the slide variability. Those sections with ruptured schizonts contained more pronounced hemorrhage and inflammation, as one would expect.

	Pigment	Schizont/Oocysts	Merogony	Gametocytes		Misc.
				Development	Morphology	
<b>Haemoproteidae</b>	Gametocytes: variable size, shape, location and number of granules	In endothelial cells of lung, kidney, liver, spleen elongate, twisted; megaloschizonts	In fixed tissue;* NOT erythrocytes or leukocytes	Erythrocytes	Elongate, horseshoe-shaped; embrace erythrocyte nucleus	Can diagnose with microgametes/gamonts in blood or schizonts in tissues
<b>Plasmodiida</b>	Meronts and gametocytes: randomly scattered aggregates and clumps	In erythrocytes multiple chromatin masses	In fixed tissue* and erythrocytes	Erythrocytes	Round, oval to elongate with pigment	Erythrocytic merogony is periodic i.e. every 24, 48, or 72 hours
<b>Leukocytozoidae</b>	NONE	In hepatocytes megaloschizonts	In hepatocytes;NOT in erythrocytes	Erythrocytes and/or leukocytes	Round and displace host cell nucleus or oval to elliptical, becoming bizarre and elongate	Can diagnose based on gamonts or gametes in smears; presence of megaloschizonts

\*Fixed tissue as used here simply means tissue that is non-circulatory, with no reference to formalin-fixation.

**Contributor:** Department of Pathology, College of Veterinary Medicine, University of Georgia, Athens, GA 30602  
<http://www.vet.uga.edu/VPP/index.php>

**References:**

1. Donovan TA, Schrenzel M, Tucker TA, Pessier AP, Stalis IH. Hepatic hemorrhage, hemocoelom, and sudden death due to *Haemoproteus* infection in passerine birds: eleven cases. *J Vet Diagn Invest.* 2008;20:304-313.
2. Gardiner CH, Fayer R, Dubey JP. *An Atlas of Protozoan Parasites in Animal Tissues.* 2<sup>nd</sup> ed. Washington D.C.: Armed Forces Institute of Pathology, American Registry of Pathology; 1998:65, 73.
3. Hall DG, Harmon BG, Howerth EW, Gregory CR, Clubb SL. Sudden death in psittacine and non-psittacine birds associated with hepatic infection with an unclassified haemosporozoan parasite: eight cases (1994-1996). Proceedings of the 1<sup>st</sup> International Virtual Conference in Veterinary Medicine, Diseases of Psittacine Birds. University of Georgia, Athens, GA, 1998.
4. Thrall MA, Baker DC, Campbell TW, et al. Hematology of Birds. In: *Veterinary Hematology and Clinical Chemistry.* Ames, IA: Blackwell Publishing; 2006:245-246.
5. Valkiūnas G. *Avian Malarial Parasites and Other Haemosporidia.* New York, NY: CRC Press; 2005.

**CASE II: 09-2131 (AFIP 3164851).**

**Signalment:** Estimated 1-month-old, female, alpaca cria (*Vicugna pacos*).

**History:** This alpaca cria was found down by the owners. The animal was weak, had been losing body condition, and was found down again several days later despite supportive care and supplemental nutrition. The cria died enroute to the veterinary hospital.

**Gross Pathology:** The animal was emaciated and severely dehydrated. The liver was mildly enlarged with rounded edges and exhibited an accentuated lobular pattern that was overlain by myriad, random, pinpoint, occasionally coalescing white foci.

**Histopathologic Description:** **Liver:** Approximately 40% of the hepatic parenchyma is disrupted by multifocal to coalescing, randomly arranged foci of coagulative to lytic necrosis that are characterized by accumulation of eosinophilic and karyorrhectic, necrotic, cellular debris and small amounts of fibrin with variable retention of cellular architecture. These areas are infiltrated by moderate numbers of neutrophils and macrophages with rare lymphocytes. Within the cytoplasm of occasional hepatocytes located

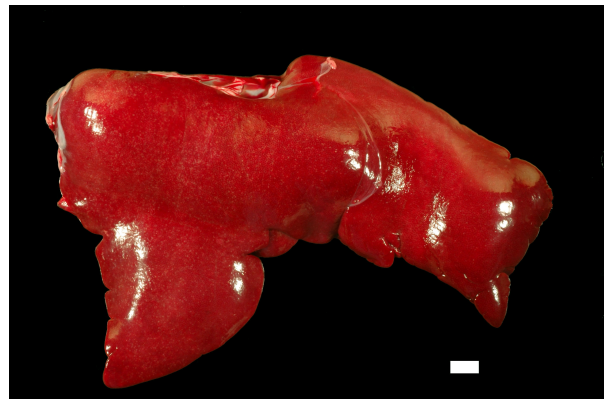along the periphery of these foci are faintly visible, haystack arrangements of fine, filamentous bacteria. The hepatic sinusoids are diffusely congested with mild dilation of sublobular and portal lymphatics.

**Contributor’s Morphologic Diagnosis:** Liver: random necrotizing hepatitis, multifocal to coalescing, marked, with intralesional, intracellular, filamentous bacteria.

**Contributor’s Comment:** The intracellular bacteria that are faintly visible with H&E staining are more readily apparent with Giemsa staining. These lesions are consistent with Tyzzer’s Disease caused by *Clostridium piliforme*. Although not performed in this case, additional visualization of the organism and confirmation of its identity can be made through the use of silver stains, immunohistochemistry, or PCR. This organism is very difficult to culture and diagnosis is typically made by the characteristic morphologic lesions and the demonstration of the causative organism by these methods.<sup>1,2</sup>

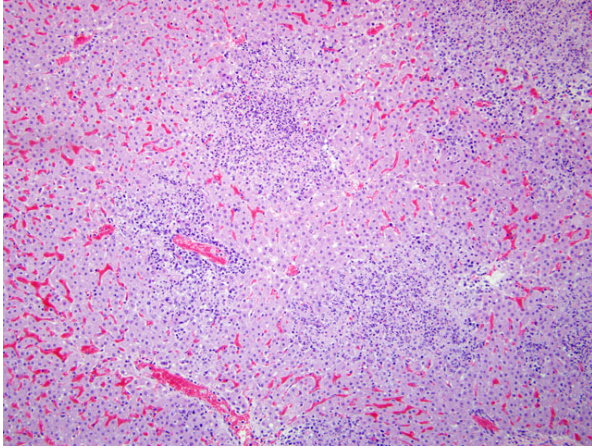
*Clostridium piliforme* (formerly *Bacillus piliformis*) is a gram negative, obligate intracellular bacterium that has been reported to cause disease in a wide range of animals. It is best recognized as a pathogen of rabbits, rats, guinea pigs, hamsters, gerbils, and foals, but the list of species in which it has been recognized is diverse including calves, dogs, cats, a Eurasian otter, a red panda, and even a rainbow lorikeet.<sup>1-3,5,6</sup>

The exact pathogenesis of Tyzzer’s disease has not been fully elucidated. Affected animals are usually very young or immunosuppressed. Lesions are necrotizing in nature and most frequently involve the liver with less consistent involvement of the gastrointestinal tract and heart.<sup>2</sup> Infection follows a rapid course and is typically fatal with few exceptions.<sup>1</sup>

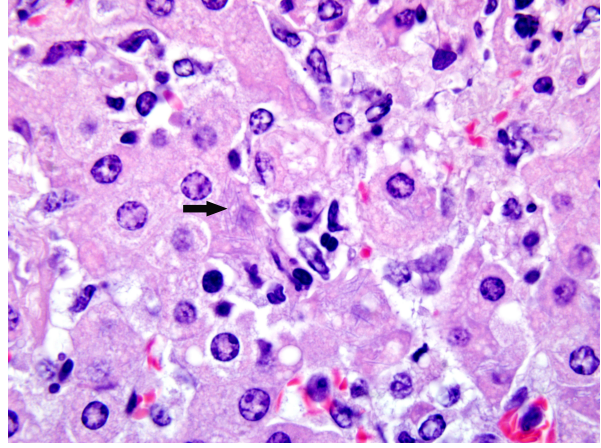


2-1. Liver; alpaca, cria. The liver is mildly enlarged with rounded edges and a bulging surface. All lobes contain randomly arranged, pin point, occasionally coalescing white foci. Photograph courtesy of Department of Population Health and Pathobiology, College of Veterinary Medicine, North Carolina State University, 4700 Hillsborough Street, Raleigh, NC 27606, [sandra\\_horton@ncsu.edu](mailto:sandra_horton@ncsu.edu)





2-2. Liver, alpaca, cria. Up to 40% of the hepatic parenchyma is disrupted and replaced by multifocal to coalescing, random areas of necrosis that contain variable numbers of degenerate neutrophils and macrophages. (HE 40X)



2-3. Liver, alpaca, cria. Along the periphery of necrotic areas degenerate hepatocytes contain intracytoplasmic haystack arrangements of fine, filamentous bacteria (black arrow). (HE 1000X)

**AFIP Diagnosis:** Liver: Hepatitis, random, necrotizing, acute, multifocal to coalescing, marked with intrahepatocellular filamentous bacilli.

**Conference Comment:** Though typically a disease of foals and laboratory animals, Tyzzer's disease can affect a variety of species as described by the contributor and demonstrated in this case. In cases of multifocal random hepatic necrosis, especially in young animals, infections with *Clostridium piliforme*, *Salmonella* species, or an alphaherpesvirus are worthy etiologies to consider in most animal species.

Infections with *Clostridium piliforme* are classically characterized by a triad of enteritis (usually affecting the ileum and occasionally the cecum), hepatitis, and myocarditis, with some species and strain variations among laboratory animals. Of note in mice, those with a B6 background are considered resistant to infection, while DBA/2 strain mice are susceptible. Neutralization of IL-12, depletion of NK cells, and neutrophil depletion increase the susceptibility to disease in mice, even in those strains considered resistant. Resistance is also partially conferred by B lymphocyte function in mice. In addition to the "Tyzzer's triad" of lesions, rats may also develop megaloleitis. Intestinal lesions in the hamster may be present in the ileum, cecum and colon. Mongolian gerbils are particularly susceptible to infection, rendering them excellent sentinels for Tyzzer's in research settings. Tyzzer's disease in gerbils may also manifest as diffuse suppurative encephalitis. Rabbits may have subclinical infections, with clinical disease precipitated by stress or corticosteroid administration. Lesions in the rabbit are most common in the intestines, occasionally found in the liver and rarely in

the heart. Gross lesions in the heart are usually prominent near the apex of the left ventricle.<sup>4</sup>

**Contributor:** Department of Population Health and Pathobiology, College of Veterinary Medicine, North Carolina State University, 4700 Hillsborough Street, Raleigh, NC 27606  
<http://www.cvm.ncsu.edu/dphp/path/anatomicpath.html>

#### References:

1. Borchers A, Magesian KG, Halland S, Pusterla N, Wilson WD. Successful treatment and polymerase chain reaction (PCR) confirmation of Tyzzer's disease in a foal and clinical and pathologic characteristics of 6 additional foals (1986-2005). *J Vet Intern Med.* 2006;20:1212-1218.
2. Cullen JM: Liver, biliary system, and exocrine pancreas. In: *Pathologic Basis of Veterinary Disease*, eds. McGavin MD, Zachary JF, 4<sup>th</sup> ed., pp. 433-434. Elsevier, St. Louis, MO, 2007.
3. Langan J, Bemis D, Harbo S, Pollock C, Schumacher J. Tyzzer's disease in a red panda (*Ailurus fulgens fulgens*). *J Zoo Wildl Med.* 2000;31:558-562.
4. Percy DH, Barthold SW. *Pathology of Laboratory Rodents and Rabbits*. 3<sup>rd</sup> ed. Ames, IA: Blackwell Publishing; 2007:57-58,138-140,208,271-273.
5. Raymond JT, Topham K, Shiota K, Ikeda T, Garner MM. Tyzzer's disease in a neonatal rainbow lorikeet (*Trichoglossus haematodus*). *Vet Pathol.* 2001;38:326-327.
6. Simpson VR, Hargreaves J, Birtles RJ, Marsden H, Williams DL. Tyzzer's disease in a Eurasian otter (*Lutra lutra*) in Scotland. *Vet Rec.* 2008;163:539-543.



**CASE III: S394/10 (AFIP 3164881).**

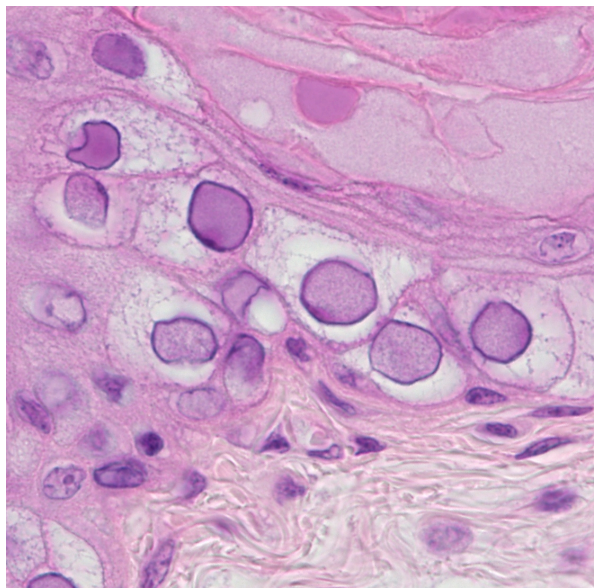
**Signalment:** Two-week-old, male, budgerigar (*Melopsittacus undulatus*).

**History:** Budgerigars and cockatiels were housed and bred for non-commercial purposes in an outdoor aviary. Incidentally, ectoparasites were diagnosed and treated in the budgies. All cockatiels presented healthy. One of the oldest budgie nestlings was suddenly found dead and was submitted for necropsy, whereas other nestlings were normal. The referring veterinarian suggested an avian polyomavirus infection.

**Gross Pathology:** Necropsy revealed a poor body condition. The skin displayed single up to 2 mm long feathers. Liver and kidney showed moderate, acute, diffuse congestion. The intestinal tract contained firm ingesta.

**Laboratory Results:** PCR of formalin-fixed kidney tissue was positive for Avian Polyomavirus.

Electron microscopy: Ultrastructural investigation was performed on affected areas of detached formalin-fixed and paraffin-embedded skin tissue sections. Epithelial cells of feather follicles displayed margination of chromatin and myriad intranuclear viral particles measuring approximately 35 nm in diameter.

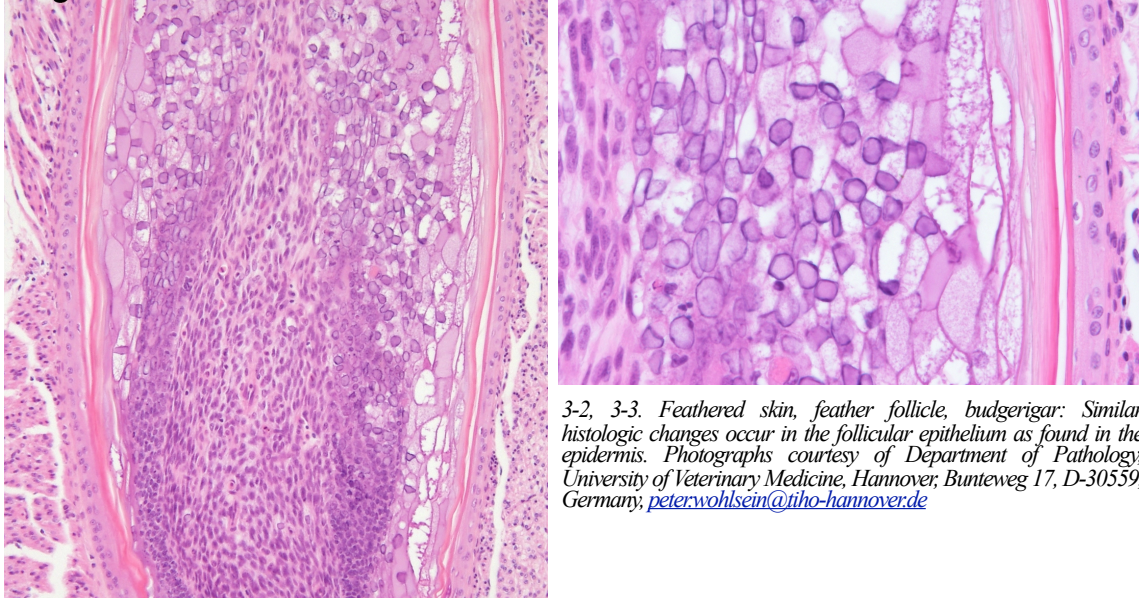


3-1. Feathered skin, epidermis, budgerigar: Numerous epidermal epithelial cells contain randomly distributed, multifocal to coalescing areas with enlarged, vacuolated cytoplasm (ballooning degeneration). Affected epithelial cells contain amphophilic to basophilic intranuclear inclusions which marginate the chromatin. Photograph courtesy of Department of Pathology, University of Veterinary Medicine, Hannover, Bunteweg 17, D-30559, Germany, [peter.wohlsein@tih-hannover.de](mailto:peter.wohlsein@tih-hannover.de)

**Histopathologic Description:** **Skin:** Epidermal epithelial cells of the skin display randomly distributed, multifocal to coalescing areas with enlarged, clear, sometimes foamy cytoplasm (ballooning degeneration). The number of affected cells varies, ranging from one to approximately 100 cells. Additionally, up to 100% of the follicular epithelial cells in nearly all of the feather follicles show similar changes. Affected epithelial cells are characterized by variable karyomegaly with margination of chromatin and intranuclear, amphophilic to basophilic inclusion bodies, partly with central clearing and measuring up to 15 µm in diameter. Besides karyorrhexis and karyolysis as well as karyopyknosis of epithelial cells in the ramogenic and proliferation zone of feather quills<sup>30</sup> (inner root sheath) brightly eosinophilic lamellar and fibrillar as well as irregular layered and partly pale eosinophilic material (keratin lamellae) have accumulated within the collar. No regular feather has passed the skin surface (keratin retention, feather dysplasia). The epidermis displays a slightly increased thickness of the fully keratinized stratum corneum (orthokeratotic hyperkeratosis). All described lesions are without infiltration of inflammatory cells. Multifocally, cutaneous blood vessels show moderate hyperemia.

- Contributor's Morphologic Diagnosis:** Skin 1. Feather dysplasia and retention, hyperkeratosis, severe, diffuse.  
 2. Ballooning degeneration of epidermal and follicular epithelial cells, moderate to severe, multifocal to coalescing associated with karyomegaly and intranuclear, amphophilic to basophilic inclusion bodies consistent with avian polyomavirus.  
 3. Hyperkeratosis, orthokeratotic, slight, diffuse.

**Contributor's Comment:** Avian polyomavirus, the agent of *Budgerigar fledgling disease*, belongs to the family Polyomaviridae and is characterized by a double-stranded DNA genome without RNA stage. The etiologic agent of *Budgerigar fledgling disease* was termed by The International Committee on Taxonomy of Viruses<sup>13</sup> *Budgerigar fledgling disease virus*, but nowadays the virus is generally designated as Avian polyomavirus due to its wide avian host range.<sup>15</sup> Additionally, a taxonomy-PubMed search resulted in Budgerigar fledgling disease viruses -1, -4 and -5, lacking the term Avian Polyomavirus (APV). The disease was originally described by Bemier et al. in Quebec, Canada and Bozeman et al. in Georgia and Texas in 1981.<sup>1,3</sup> They reported a multisystemic disease with intranuclear inclusion bodies in multiple organs and were able to identify virus particles of 42 to 55 nm in diameter of affected budgies. In 1986, molecular characterization of the etiologic agent of *Budgerigar fledgling disease* identified initially the first non-mammalian polyomavirus.<sup>21</sup> Mammalian



3-2, 3-3. Feathered skin, feather follicle, budgerigar: Similar histologic changes occur in the follicular epithelium as found in the epidermis. Photographs courtesy of Department of Pathology, University of Veterinary Medicine, Hannover, Bunteweg 17, D-30559, Germany; [peter.wohlsein@tiho-hannover.de](mailto:peter.wohlsein@tiho-hannover.de)

polyomaviruses occur in mice, monkeys, humans, rabbits, and hamsters displaying a narrow host range associated with the ability to induce tumors in mammals.<sup>4</sup> In hamsters, Hamster polyomavirus can cause transmissible lymphomas, keratinizing skin tumors of hair follicles or subclinical infections.<sup>24</sup> Polyomaviruses of rabbits are named “rabbit kidney vacuolating virus” and in mice polyomaviruses are well characterized due to their use in experimental studies.<sup>24</sup>

Clinically, one hallmark of the disease in young budgies is the absence of contour, down feathers and/or filoplume which results in the commonly used names “runners,” “creepers,” “crawlers” or “bullets” of affected, naked nestlings. While a chronic APV infection is rarely seen in adult birds, primarily budgie nestlings younger than 14 (10-28) days of age show an acutely fatal outcome. Animals exhibit typical stunted growth, abnormal feathers, liver necrosis, effusion in the body cavity and sudden death. The mortality rate in budgie fledglings is described as approximately 100%.<sup>16</sup> Interestingly, APV infections often occur in large (commercial) aviaries with hand feeding and concurrent infection with the circovirus of Psittacine Beak and Feather disease (PBFDV) is frequently seen. As a cause PBFDV-induced immunosuppression is suggested.<sup>27</sup> French Molt, a syndrome of feather maturation problems in budgies and other psittacine birds, is one manifestation of APV infection, but is suggested to have a milder, more protracted course of disease.<sup>18</sup>

In general, APV has a wide geographical distribution and the presence of APV in Canada and USA<sup>1,3</sup> has already been mentioned. Furthermore, cases of APV infections have been described in Japan,<sup>12</sup> Australia,<sup>23</sup>

Germany,<sup>28</sup> Slovakia<sup>22</sup> and Taiwan.<sup>14</sup> APV affects a broad range of other birds, even though the onset of the disease in other species is predominantly later in life (up to one year) and the severity of clinical as well as histopathological changes varies. Other species include conures, parrots, cockatoos, cockatiels, lorries, macaws, splendid parakeets, Gouldian finches, and lovebirds.<sup>17</sup> In 2004, Avian polyomavirus DNA was detected in 0.79% (seven out of 877 animals) of psittacine birds in Italy;<sup>2</sup> the authors stated that due to the extremely low detection rate of the virus the disease seems not to play a role in Italian breeding centers. Psittacine Beak and Feather Disease Virus, which is able to mimic APV infections clinically, was detected in 8.05% (122 out of 1516 animals) of tested animals in Italy,<sup>2</sup> in contrast to a German survey with 39.2% (58 out of 146 animals) of positive PCR results in captive psittacine birds.<sup>25</sup> Usually, virus transmission occurs via inhalation of droppings, oral secretions and/or feather or skin danders, because these materials contain a high load of virus particles. A vertical mode of transmission is suggested but not proven until now.<sup>27</sup> APV infection is a multisystemic disease, and the virus does not show a particular cell tropism. Affected cell types include mesenchymal and epithelial cells. As a consequence nearly all organs/tissues are affected and show histopathologically characteristic intranuclear amphophilic to basophilic inclusion bodies with a clear center, associated with karyomegaly as well as margination of chromatin. Depending on the organ/tissue, inflammation or tissue destruction (necrosis/apoptosis) appears as a corollary of the infection. Table 1 gives an overview upon the organ/tissue-specific morphological findings of APV infections in budgies. During a chronic APV-infection in budgies, glomerulopathy occurs most likely due to an immune complex deposition, which is interpreted as

WSC 2010-2011

Table 1. Summary of pathomorphological changes in juvenile budgerigars due to Avian Polyomaviruses (APV).<sup>27</sup>

Organ/tissue	Histological findings in budgerigars <sup>1</sup>	Clinical/gross changes
Cerebellum	Purkinje cells: ICB*	intention tremors
Feathers	nearly all epithelial cells of feather follicles: ICB*; hemorrhage, feather dysplasia	absent feathers, thick sheaths
Skin	epidermal cells: varying degree of ICB* with ballooning degeneration	“skin discoloration”
Myocardium (rarely pericardium)	cardiomyocytes: ICB*, necrosis; lymphoplasmacytic inflammation, hemorrhage	plaques, adhesions, flocculent fluid
Bursa of Fabricius	rarely ICB* in lymphocytes, hemorrhage, depletion, necrosis of lymphocytes in medulla	swelling, hemorrhage
Oral cavity	ICB* of epithelial cells	hemorrhage, necrosis
Pancreas	acinar cells: ICB*; variable inflammation, necrosis, hemorrhage	hemorrhage, necrosis
Liver	hepatocytes and Kupffer cells: ICB*, coagulative necrosis	necrosis, hemorrhage
Spleen	macrophages of splenic periarteriolar sheaths: abundant ICB*; necrosis of perivascular histiocytes, lymphoid depletion	splenomegaly, hemorrhage
Kidney	Tubular- and mesangial cells: ICB*, mesangial cell necrosis; swollen glomeruli, secondary glomerulopathy: aggregation of immune complexes, Type III hypersensitivity; PAS positive reaction of glomeruli	nonspecific enlargement
Trachea	ICB* of epithelial cells, mucosal proliferation	
Skeletal muscle	ICB* of myocytes; necrosis, lymphoplasmacytic inflammation	pallor, hemorrhage

<sup>1</sup>Other species show similar, but somehow different lesions.

\*ICB abbreviates karyomegaly with margination of chromatin and intranuclear, amphophilic to basophilic inclusion bodies with a clearing of the center measuring up to 15 µm in diameter.



type III hypersensitivity. Interestingly, after a multisystemic spread of APV, cellular damage by apoptosis<sup>15</sup> in skin and feather epithelial cells is induced and this apoptosis causes efficient virus release from infected cells without inflammation.

In the present case, typical inclusion bodies as well as karyomegaly and chromatin margination with a pale center were detectable in the epidermis, feather follicles, renal tubular epithelial cells, glomeruli, epithelial cells of the lung, oesophagus, peri-oesophageal connective tissue, small intestinal epithelium, Purkinje cells and preen gland epithelial cells as well as hematopoietic cells in bone marrow. Very few inclusion bodies were detectable in spinal cord neurons and pancreas. Additionally, multifocal, moderate, necrotizing pancreatitis with moderate, acute hemorrhage was detected. Myocytes display inclusion bodies and minimal, lymphoplasmacytic infiltrations, and marked, multifocally distributed necrosis. In the bursa cloacalis a moderate, central follicular necrosis of lymphocytes was detected without inclusions. Hepatocytes and periportal connective tissue contained

a moderate number of inclusions. In addition, moderate, multifocal, lymphoplasmacytic hepatitis with few areas of coagulative necrosis was observed. Remarkably, as an example of a mesenchymal tissue, gizzard muscle cells displayed a very high number of inclusion bodies without cellular reaction. PAS-reaction in the present case does not confirm a glomerulopathy as it is described in APV infections. Clinical, histological, and electron microscopical findings as well as the detection of viral DNA using PCR favors the etiology of Avian polyomavirus. An important differential represents the Avian Adenovirus, which accumulates 75-80 nm large virus particles in the nucleus.

Other avian polyomaviruses include Goose Hemorrhagic Polyomavirus,<sup>11</sup> which causes Hemorrhagic Nephritis Enteritis of Geese (HNEG). It represents a fatal disease in European geese. Since the late 1960s several outbreaks in goose flocks have been documented and finally in 2000 it was possible to characterize the etiological agent.<sup>11</sup> Typical clinical signs include high morbidity and mortality in up to 10-

**Table 2.** Virus-induced inclusions in birds with special emphasis on skin pathology.<sup>27</sup>

Virus (disease)	Histopathology	Macroscopic
Avian Poxvirus	epidermal hyperplasia, intraepidermal vesicles, ballooning degeneration, <i>Bollinger bodies</i> = <b>abundant, large, eosinophilic, intracytoplasmic ICB*</b>	proliferative, necrotizing dermatitis, pustules, papules, nodules
Circovirus of Psittacine Beak and Feather Disease (Pbfd)	Acute: epidermal hyperplasia, hyperkeratosis, degeneration of germinal cells, ballooning and patchy degeneration of cells in epidermal collar with <b>ICB*</b> chronic: granulomas, giant cells, confluent lymphoplasmacytic infiltrates; macrophages contain <b>large, globular, basophilic, cytoplasmic ICB*</b>	dystrophic feathers, necrosis/hemorrhage of feather shafts; beak necrosis, keratin loss
Avian Adenovirus	mild, mononuclear, interstitial nephritis, conjunctivitis, encephalitis, CNS vessels: necrosis with endothelial <b>ICB*</b> ; multisystemic; karyomegaly, <b>intranuclear, dark eosinophilic to basophilic ICB*</b>	among others, renal enlargement
Psittacine Herpesvirus (Pacheco's disease)	multisystemic; skin, epidermal hyperplasia, acanthosis, <b>large, intranuclear ICB* with a clear halo</b>	proliferative dermatitis, skin roughening, plaques, depigmentation
Papillomavirus	hyperplasia of epidermis associated with vascular stroma; enlarged nuclei of epidermal cells are suggestive of <b>ICB*</b>	proliferative dermatitis
Avian Polyomavirus (Budgerigar Fledgling Disease - BFD)	multisystemic, skin, karyomegaly with margination of chromatin and <b>intranuclear, amphophilic to basophilic ICB* with a clearing of the center</b> measuring up to 15 µm in diameter	dystrophic feathers, feather loss, "runner"

\* ICB abbreviates inclusion bodies

week-old geese. The virus shows a tropism for endothelial and lymphoid cells. It is a systemic virus infection with immunosuppressive properties.<sup>19</sup>

Other virus infections in budgies, with or without inclusion bodies, have to be considered and excluded as differentials including Adenovirus, Psittacine Herpesvirus (Pacheco's disease), Psittacine Beak and Feather disease, Avian Papillomaviruses and Avian Poxvirus. Table 2 on the preceding page gives an overview of the differentials of avian virus infections with inclusion bodies as a characteristic histopathological feature. In the present case, clinical findings, histopathological changes, ultrastructural detection of virus particles, and the presence of polyomaviral DNA<sup>9</sup> are characteristic for APV in budgies. Other diagnostic possibilities to confirm the diagnosis include immunohistochemistry,<sup>7</sup> *in situ*-hybridisation with DNA probes,<sup>26</sup> virus isolation in chicken embryo fibroblasts,<sup>6</sup> and direct fluorescent antibody tests.<sup>10</sup>

**AFIP Diagnosis:** Feathered skin: Epidermal and follicular epithelial degeneration and intracellular edema, multifocal, moderate, with follicular dysplasia, feather retention, orthokeratotic hyperkeratosis, karyomegaly, and amphophilic intranuclear epithelial inclusions.

**Conference Comment:** The contributor provides a thoroughly exquisite review of avian polyomavirus infection and a comprehensive differential diagnosis list for viral diseases of the skin among avian species.

Some of the conference discussion centered on the most appropriate terminology to characterize the histologic changes found in the follicular and epidermal epithelium, including the use of the terms 'ballooning degeneration', 'vacuolar degeneration', and 'hydropic degeneration'. According to the authors of *Jubb, Kennedy and Palmer's Pathology of Domestic Animals*, cytoplasmic clearing or clear space within cells of the epidermis can be classified as hydropic degeneration, ballooning degeneration or vacuolar degeneration.<sup>8</sup> 'Hydropic degeneration' refers specifically to intracellular edema of the basal layer and occasionally the basal cells of hair follicle outer root sheath. 'Vacuolar degeneration' is used to denote intracellular edema in cells above and below the basement membrane zone. 'Ballooning degeneration' is used to denote intracellular edema in the epidermis and is considered to be a characteristic feature of viral infection in the skin; historically, the term has been reserved for poxviral and herpesviral infections. In contrast, *Robbins and Cotran Pathologic Basis of Disease* uses the term 'ballooning degeneration' to characterize the acute cell swelling in human acute hepatitis,<sup>5</sup> and the text further defines hydropic

(ballooning) swelling in the skin as "intracellular edema of keratinocytes, often seen in viral infections".<sup>20</sup> Finally, to add further complexity to the terminology, avian pathologists describe the histologic changes in the skin caused by polyomaviral infection as cytoplasmic vacuolar (ballooning) degeneration, with karyomegaly and intranuclear inclusions.<sup>29</sup> Despite the differences in terminology among the various references, the histologic changes reflect intracellular edema, cell swelling, and degeneration of epithelial cells of the skin, and hence the histomorphologic diagnosis indicated above.

**Contributor:** Department of Pathology, University of Veterinary Medicine Hannover, Bünteweg 17, D-30559 Hannover, Germany  
<http://www.tiho-hannover.de/einricht/patho/index.htm>

#### References:

1. Bernier G, Morin M, Marsolais G. A generalized inclusion body disease in the budgerigar (*Melopsittacus undulatus*) caused by a papovavirus-like agent. *Avian Dis.* 1981;25(4):1083-1092.
2. Bert E, Tomassone L, Peccati C, et al. Detection of beak and feather disease virus (BFDV) and avian polyomavirus (APV) DNA in psittacine birds in Italy. *J Vet Med B Infect Dis Vet Public Health.* 2005;52(2):64-68.
3. Bozeman LH, Davis RB, Gaudry D, et al. Characterization of a papovavirus isolated from fledgling budgerigars. *Avian Dis.* 1981;25(4):972-980.
4. Cole C, Conzen SD. *Polyomaviridae: The Viruses and Their Replication.* In: Fields B, Knipe DM, Howley PM, et al., eds. *Fields Virology.* 3rd ed. Baltimore, MD: Lippincott Williams & Wilkins; 1996: 2141-2174.
5. Crawford JM, Liu C. Liver and biliary tract. In: Kumar V, Abbas AK, Fausto N, Aster JC, eds. *Robbins and Cotran Pathologic Basis of Disease.* 8th ed. Philadelphia, PA: Elsevier Saunders; 2009:851.
6. Dykstra MJ, Bozeman LH. A light and electron microscopic examination of budgerigar fledgling disease virus in tissue and in cell culture. *Avian Pathol.* 1982;11(1):11-28.
7. Fitzgerald SD, Reed WM, Fulton RM. Development and application of an immunohistochemical staining technique to detect avian polyomaviral antigen in tissue sections. *J Vet Diagn Invest.* 1995;7(4):444-450.
8. Ginn PE, Mansell JEKL, Rakich PM. Skin and appendages. In: Maxie MG, ed. *Jubb, Kennedy and Palmer's Pathology of Domestic Animals.* Vol.1, 5th ed. Philadelphia, PA: Elsevier Ltd; 2007:563, 567.
9. Gough JF. Outbreaks of budgerigar fledgling disease in three aviaries in Ontario. *Can Vet J.* 1989;30(8):672-674.
10. Graham DL, Calnek BW. Papovavirus infection in hand-fed parrots: virus isolation and pathology. *Avian Dis.* 1987;31(2):398-410.

11. Guerin JL, Gelfi J, Dubois L, et al. A novel polyomavirus (goose hemorrhagic polyomavirus) is the agent of hemorrhagic nephritis enteritis of geese. *J Virol*. 2000;74(10):4523-4529.
12. Hirai K, Nonaka H, Fukushi H, et al. Isolation of a papovavirus-like agent from young budgerigars with feather abnormalities. *Nippon Juigaku Zasshi*. 1984;46(4):577-582.
13. Hou J, Jens PJ, Major EO, zur Hausen HJ, Almeida J, van der Noordaa D, Walker D, Lowy D, Bernard U, Butel JS, Cheng D, Frisque RJ, Nagashima K. Polyomaviridae. *Virus taxonomy. Eighth Report of the ICTV*. 2005;231-238, <http://www.ictvonline.org/index.asp>.
14. Hsu CM, Ko CY, Tsaia HJ. Detection and sequence analysis of avian polyomavirus and psittacine beak and feather disease virus from psittacine birds in Taiwan. *Avian Dis*. 2006;50(3):348-353.
15. Johne R, Muller H. Polyomaviruses of birds: etiologic agents of inflammatory diseases in a tumor virus family. *J Virol*. 2007;81(21):11554-11559.
16. Kaleta EF, Herbst W, Kaup FJ, et al. [Viral etiology of a disease accompanied by hepatitis and feather disorders in budgerigar fledgelings (*Melopsittacus undulatus*)]. *Zentralbl Veterinarmed B*. 1984;31(3):219-224.
17. Kingston RS. Budgerigar fledgling disease (papovavirus) in pet birds. *J Vet Diagn Invest*. 1992;4(4):455-458.
18. Krautwald ME, Muller H, Kaleta EF. Polyomavirus infection in budgerigars (*Melopsittacus undulatus*): clinical and aetiological studies. *Zentralbl Veterinarmed B*. 1989;36(6):459-467.
19. Lacroux C, Andreoletti O, Payre B, et al. Pathology of spontaneous and experimental infections by Goose haemorrhagic polyomavirus. *Avian Pathol*. 2004;33(3):351-358.
20. Lazar AJF, Murphy GF. The skin. In: Kumar V, Abbas AK, Fausto N, Aster JC, eds. *Robbins and Cotran Pathologic Basis of Disease*. 8th ed. Philadelphia, PA: Elsevier Saunders; 2009:1168.
21. Lehn H, Muller H. Cloning and characterization of budgerigar fledgling disease virus, an avian polyomavirus. *Virology*. 1986;151(2):362-370.
22. Literak I, Smid B, Dubska L, et al. An outbreak of the polyomavirus infection in budgerigars and cockatiels in Slovakia, including a genome analysis of an avian polyomavirus isolate. *Avian Dis*. 2006;50(1):120-123.
23. Pass DA. A papova-like virus infection of lovebirds (*Agapornis* sp). *Aust Vet J*. 1985;62(9):318-319.
24. Percy DH, Barthold SW. *Pathology of Laboratory Rodents and Rabbits*. 3rd ed. Ames, IA: Blackwell Publishing; 2007:256.
25. Rahaus M, Wolff MH. Psittacine beak and feather disease: a first survey of the distribution of beak and feather disease virus inside the population of captive psittacine birds in Germany. *J Vet Med B Infect Dis Vet Public Health*. 2003;50(8):368-371.
26. Ramis A, Latimer KS, Niagro FD, et al. Diagnosis of psittacine beak and feather disease (PBFD) viral infection, avian polyomavirus infection, adenovirus infection and herpesvirus infection in psittacine tissues using DNA in situ hybridization. *Avian Pathol*. 1994;23(4):643-657.
27. Schmidt R, Reavill DR, Phalen DN. *Pathology of Pet and Aviary Birds*. Ames, IA: Iowa State Press, A Blackwell Publishing Company; 2003.
28. Stoll R, Luo D, Kouwenhoven B, et al. Molecular and biological characteristics of avian polyomaviruses: isolates from different species of birds indicate that avian polyomaviruses form a distinct subgenus within the polyomavirus genus. *J Gen Virol*. 1993;74 (Pt 2):229-237.
29. Tahseen AA, Barnes HJ, Fletcher OJ, Shivaprasad HL, Swayne DE, Williams S: Integumentary system. In: *Avian Histopathology*. 3rd ed. Jacksonville, FL: American Association of Avian Pathologists; 2008:398.
30. Yu M, Wu P, Widelitz RB, et al. The morphogenesis of feathers. *Nature*. 2002;420(6913):308-312.

**CASE IV: WCS2009101801 (AFIP 3167494).**

**Signalment:** Adult, bay pipefish (*Syngnathus griseolineatus*).

**History:** This bay pipefish was part of a recently acquired group of pipefish that arrived and was undergoing quarantine. Most animals in the shipment arrived in thin body condition with few to multiple pinpoint coalescent areas of skin ulceration and scale loss. Cytology of the skin scrapes revealed numerous ciliates, bacteria, and fungal hyphae.

**Gross Pathology:** On presentation to necropsy, this pipefish was in thin body condition and had few visible pinpoint to 0.3 cm patchy areas of skin reddening that extended along the dorsal body wall as well as ventrally around and within the pouch.

**Histopathologic Description:** Two transverse sections through the body of a bay pipefish (*Syngnathus griseolineatus*) at the level of the pouch are examined. Included in these sections are vertebral body, spinal cord, skeletal muscle, dorsal fin and pouch. Bilaterally, the skeletal muscle bundles that run parallel to the vertebral column are expanded by clear, confluent spaces (edema) and localized hemorrhage. Regionally myofibers display various stages of fragmentation, degeneration and lysis. Associated with this lesion are moderate numbers of round to ovoid, ciliated protozoal organisms which measure approximately 30-50 µm x 20-30 µm, have a large



(7-10 µm) basophilic macronucleus and a basophilic floccular to granular cytoplasm. Occasionally within the cytoplasm of these organisms there are numerous eosinophilic homogenous droplets (phagocytosed erythrocytes, presumptive). These organisms are often associated with individually affected myofibers and/or are located within the interstitium. In several microscopic fields, organisms can be identified within the lumen of vascular channels. The ventral surface of the skin, particularly in the region of the pouch, is segmentally eroded and hyperplastic. The underlying dermal collagen fibers are markedly loosened and separated by clear space (edema) and exhibit a mild to moderate inflammatory infiltrate composed primarily of lymphocytes, macrophages and plasma cells. Ciliated protozoal organisms morphologically similar to those previously described are scattered throughout the dermis and subdermal connective tissues. Adhered to the eroded sections of epidermis are small aggregates of bacterial cocci.

**Contributor's Morphologic Diagnosis:** 1. Skeletal muscle: Myofiber degeneration and necrosis, subacute, multifocal, severe with lymphoplasmacytic and histiocytic inflammation, hemorrhage and many intralesional ciliated protozoal organisms. 2. Scaled skin, pouch: Dermatitis, lymphoplasmacytic and histiocytic, chronic-active, regional, moderate with edema, segmental epidermal erosion and hyperplasia and intralesional ciliated protozoal organisms.

**Contributor's Comment:** Bay pipefish belong to the family Syngnathidae which include both sea horses and sea dragons. The species are most commonly found in shallow, coastal waters and are characterized by their elongated snouts, fused jaws, the absence of pelvic fins, and by thick plates of bony armor covering the body. Female fish of this family deposit eggs into the ventral pouch or onto a sticky brood patch of the males who are responsible for carrying the eggs until they hatch.

Scuticociliates are facultative parasites of marine fish. Disease associated with these organisms has been described in numerous marine species including lobster,<sup>7</sup> sea dragons,<sup>6,8</sup> tuna<sup>2</sup> and olive flounder.<sup>1</sup> Infection is frequently confined to the dermis with death in these cases thought to be associated with sloughing of the epidermis and subsequent disruption of osmoregulation rather than direct organ damage.<sup>8</sup> However, deaths associated with disseminated disease have been reported, particularly in farmed fish, causing significant economic loss in this industry.<sup>2,3</sup> Histopathology in cases of disseminated disease is similar to that described for this pipefish, with edema, mononuclear inflammation and hemorrhage associated with the presence of organisms.<sup>1-3</sup> Erythrocytes within cytoplasmic 'food vacuoles' are a consistent feature of

these organisms on histology making them easy to identify.<sup>3</sup>

**AFIP Diagnosis:** 1. Scaled skin and brood pouch: Dermatitis, erosive and ulcerative, histiocytic and granulocytic, subacute, multifocally extensive, moderate, with intralesional ciliated protozoa. 2. Skeletal muscle fascia: Myositis and fasciitis, histiocytic and granulocytic, subacute, multifocally extensive, moderate, with myocyte degeneration and necrosis, edema, and many ciliated protozoa.

**Conference Comment:** In discussing and characterizing the inflammatory cells associated with the lesion, participants reviewed the components of teleost blood. They are remarkably similar to higher order vertebrates with the exception of nucleated erythrocytes and thrombocytes. Their neutrophils are quite similar to mammalian neutrophils, both in structure and function, and are frequently found at sites of inflammation. Monocytes circulate as they do in other vertebrates; they are able to take up residence in tissues, though their phagocytic ability is not quite as robust as it is in mammals. In addition, teleosts have lymphocytes; the presence of eosinophils, basophils and mast cells is questionable in some species.<sup>4</sup>

Responsive epidermal changes in fishes consist of an inflammatory response or hyperplasia. The inflammatory response typically begins with spongiosis and progresses to necrosis; chronic inflammation of the dermis may also result in spongiosis, though not as severe as with epidermal inflammation, and a lymphocytic infiltrate.<sup>5</sup> Epidermal hyperplasia due to toxins, hormones, or infectious agents is more generalized and occurs more frequently at lower temperatures.<sup>5</sup>

The dermal and hypodermal changes consist of an inflammatory response, ulceration and wound healing. As with mammals, the inflammatory response consists of vascular, exudative and cellular phases; the amount of time for the inflammatory response to occur is correlated with environmental temperature. Rapid colonization of ulcers often masks the inciting cause. Collagen fibers become "water-logged" resulting in the histologic appearance of a bluish sheen on the open surface of the ulcer. The rate of wound healing, as with the dermal inflammatory response, depends on water temperature. In contrast, epidermal wound covering occurs rapidly independent of water temperature in order to prevent secondary infections and to restore the osmotic barrier.<sup>5</sup>

The moderator commented that with this particular parasite, death often occurs so rapidly as to preclude a significant inflammatory response. In some cases, only skin lesions may be present; this often provides a

route of secondary bacterial infection resulting in sepsis and death. In this particular case, the moderator and participants agreed that the inflammatory response was not proportional to the myriad amoebae present.

**Contributor:** Wildlife Conservation Society, Global Health Program – Pathology, 2300 Southern Boulevard, Bronx, NY 10460  
<http://www.wcs.org>

**References:**

1. Jung S, Kitamura S, Song J, Oh M. *Miamiensis avidus* (Cilophora: Scuticociliatida) causes systemic infection of olive flounder *Paralichthys olivaceus* and is a senior synonym of *Philasterides dicentrarchi*. *Dis Aquat Org.* 2007;73(3):227-234.
2. Munday BL, Donoghue PJ, Watts M, Rough K, Hawkesford T. Fatal encephalitis due to the scuticociliate *Uronema nigricans* in sea-caged, southern bluefin tuna *Thunnus maccoyii*. *Dis Aquat Org.* 1997;30(1):17-25.
3. Puig L, Traveset R, Palenzuela O, Padros F. Histopathology of experimental scuticociliatosis in turbot *Scophthalmus maximus*. *Dis Aquat Org.* 2007;76(2):131-140.
4. Roberts RJ, Ellis AE. The anatomy and physiology of teleosts. In: Roberts RJ, ed. *Fish Pathology*. 3<sup>rd</sup> ed. Philadelphia, PA: W.B. Saunders; 2007:25-30.
5. Roberts RJ, Rodger HD. The pathophysiology and systematic pathology of teleosts. In: Roberts RJ, ed. *Fish Pathology*. 3<sup>rd</sup> ed. Philadelphia, PA: W.B. Saunders; 2007:62-65.
6. Rossteuscher S, Wenker C, Jermann T, Wahli T, Oldenberg E, Schmidt-Posthaus H. Severe Scuticociliate (*Philasterides dicentrarchi*) infection in a population of sea dragons (*Phycodurus eques* and *Phyllopteryx taeniolatus*). *Vet Pathol.* 2008;45(4): 546-550.
7. Small HJ, Neil DM, Taylor AC, Bateman K, Coombs GH. A parasitic scuticociliate infection in the Norway lobster (*Nephrops norvegicus*). *J Invertebr Pathol.* 2005;90(2):108-117.
8. Umehara A, Kosuga Y, Hirose H. Scuticociliata infection in the weedy sea dragon *Phyllopteryx taeniolatus*. *Parasitol Int.* 2003;52(2):165-168.